

# DMEK: The New Standard for Lamellar Keratoplasty

Top reasons why every DSAEK surgeon should be doing DMEK instead.

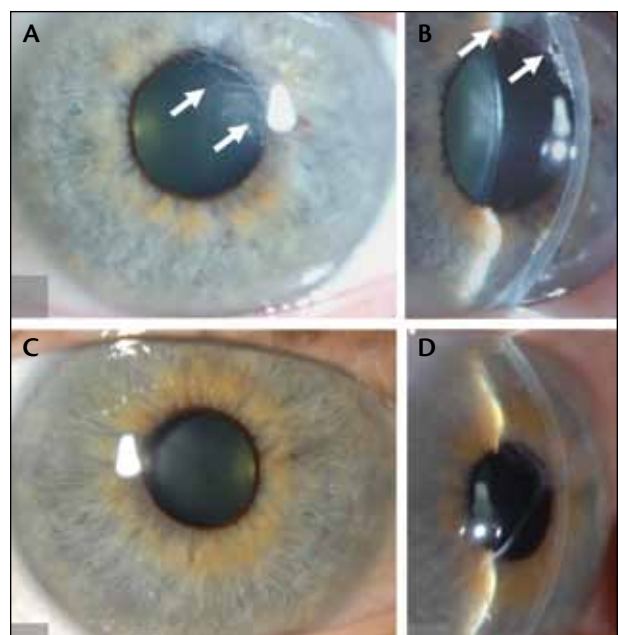
BY JACK S. PARKER, MD; AND GERRIT R.J. MELLES, MD, PhD

**D**escemet membrane endothelial keratoplasty (DMEK), the newest and most advanced form of endothelial transplantation, represents the culmination of the evolution of keratoplasty techniques. It has nudged aside its predecessor, Descemet stripping automated endothelial keratoplasty (DSAEK), just as DSAEK displaced its own forerunner, deep lamellar endothelial keratoplasty (DLEK). What differentiates DMEK from previous versions of the operation is its unparalleled precision. With a graft consisting of a single layer of endothelial cells and their basement membrane, DMEK achieves an exact, one-to-one replacement of a patient's diseased Descemet membrane with donor tissue. The result is near-perfect restoration of the recipient cornea's natural anatomy (Figure 1).<sup>1</sup>

Many ophthalmologists are reluctant to learn DMEK, largely because the previous gold standard, DSAEK, proved so successful. But now, after more than 10 years of study and thousands of operations, the data comparing the two surgeries seem hard to ignore: For most patients, DMEK offers better postoperative outcomes and fewer problems.<sup>2-11</sup> We invite all corneal surgeons—whatever their previous level of experience—to bite the bullet and make the switch, for the reasons outlined below.

## BETTER AND FASTER VISUAL RESULTS

After DSAEK, a patient's BCVA often settles at approximately 20/40 and rarely reaches 20/20 or better after 6 months. Additionally, visual recovery can be a protracted process, with many patients requiring 3 to 6 months or longer to achieve stable visual acuity.<sup>2,12</sup>



**Figure 1. Both eyes of a Fuchs dystrophy patient after DMEK:** After surgery in the left eye, a large number of central wrinkles (white arrows) are observed in the transplanted tissue (A and B); follow-up exams in the right eye show no abnormalities (C and D). Despite the different appearance of the grafts, both eyes achieved 20/20 vision within 3 months of surgery.

DMEK consistently offers better and faster visual results. Almost all eyes attain BCVAs of 20/40 or better, approximately 75% achieve 20/25 or better, and almost 50% achieve 20/20 or better. Moreover, visual rehabilitation is frequently fast, usually occurring within the first

Reprinted with permission from *Ophthalmology*.

TABLE 1. DMEK VS DSAEK: SIDE-BY-SIDE COMPARISON

	DMEK	DSAEK
Typical BCVA	≥20/25 <sup>2,3</sup>	20/40 <sup>2,3</sup>
Rate of graft rejection*	<1% <sup>7</sup>	12% <sup>7</sup>
Rate of post-operative complications		
-Intra-ocular hypertension	6% <sup>8</sup>	15-35% <sup>2</sup>
-Cataract formation <sup>†</sup>	4% patients of all ages <sup>9</sup>	7% patients younger than 50; 55% older than 50 <sup>2</sup>
Requires expensive materials?		
-Microkeratome	No	Yes
-Tissue inserter	Cheap (glass pipette)	Costly (many choices)

\* Two years after surgery  
† Three years after surgery

postoperative month.<sup>2,3</sup> In one study, patients who had undergone DSAEK in one eye and DMEK in the other overwhelmingly preferred their vision in the DMEK eye.<sup>4</sup> Additionally, in patients with poor vision after DSAEK, many saw their vision dramatically improve after reoperation with DMEK to replace their graft.<sup>5</sup>

Currently, the principal objection to transitioning to DMEK is the perception of a steep learning curve. Somewhat surprisingly, however, most surgeons report better results with DMEK than DSAEK, even during that learning curve,<sup>6</sup> and many later feel more comfortable with DMEK than DSAEK.

### LESS GRAFT REJECTION, FEWER SEVERE COMPLICATIONS

Two years after DSAEK, the reported rates of graft rejection exceed 5%,<sup>13,14</sup> but for DMEK the rate is less than 1%.<sup>7</sup> The thinner DMEK graft, containing no stromal tissue, is likely less immunogenic because it presents fewer antigens to the recipient's immune system.

Additionally, because the risk of graft rejection after DMEK is low, a less intense postoperative steroid regimen is required and, correspondingly, many associated complications occur less frequently than with previous procedures. For example, the rate of induced ocular hypertension after DMEK is 6% compared with 15% to 35% reported after DSAEK.<sup>2,8</sup> Similarly, in phakic eyes, the rate of cataract formation 3 years after DMEK is 4% for

Because the DMEK graft is thinner than a DSAEK graft and contains no stromal tissue, it is less likely immunogenic because it presents fewer antigens to the recipient's immune system.

patients of all ages, compared with 7% after DSAEK in patients younger than 50 years and 55% in patients older than 50 years at 3 years.<sup>2,9</sup>

The rate of partial graft detachment has long been a contentious issue, with some studies estimating an incidence of 50% after DMEK.<sup>2,10</sup> Fortunately, most detachments are not only small but also are located at the graft edges outside the visual axis and temporary, with the detached segments eventually reattaching.<sup>10</sup> The rate of visually significant detachments after DMEK—those that undermine the patient's eyesight or require reoperation with rebubbling or regrafting—has been reported at 12%, a figure similar to that with DSAEK.<sup>2,10</sup>

### MORE ECONOMICAL

Unlike DSAEK, DMEK requires no specialized or expensive equipment. The graft can be prepared either in an eye bank or in the operating room using standard forceps to peel Descemet membrane off the donor pos-

## TAKE-HOME MESSAGE

- A DMEK graft consists of a single layer of endothelial cells and their basement membrane.
- DMEK achieves an exact replacement of the patient's diseased Descemet membrane with donor tissue.
- With DMEK, there are fewer severe complications and better and faster visual recovery compared with DSAEK.
- Many steps of the DMEK procedure will be familiar to surgeons with endothelial keratoplasty experience.

terior stroma. Later, during surgery, the tissue is injected into the eye using a plain glass pipette. Consequently, DMEK can be performed in practically any setting and at low cost.

On the other hand, DSAEK grafts, especially ultrathin ones, must be cut using a mechanical microkeratome or femtosecond laser. Additionally, delivering the tissue into the eye may require custom-designed instruments, of which there are a litany to choose from. All of these things add substantially to the cost of the operation and make resource demands that some facilities might not be able to accommodate, particularly in developing countries.

Recently, the creation of DMEK grafts has been standardized into a no-touch procedure, in which neither the Descemet membrane nor the anterior stroma are physically contacted.<sup>15</sup> As a result, the leftover anterior element may be reused for anterior lamellar surgery, thus permitting a single donor cornea to be sectioned for use in two separate patients and effectively doubling the pool of transplantable tissue.

Viewed in this light, the creation of DSAEK grafts seems wasteful. By incorporating a chunk of stroma into the endothelial transplant, not only is the optical performance of the graft compromised, but also the anterior aspect of the donor cornea is frequently mangled, leaving it unsuitable for later transplantation.

## CONCLUSION

DSAEK is not obsolete, as it remains the preferred option in selected cases including aphakic and post-vitrectomy eyes and in eyes with severe corneal edema. In the former, the extra room inside the eye makes supporting a DMEK graft with an air bubble difficult, predisposing to detachments; in the latter, visibility is insufficient for tissue manipulation and the unrolling operations that DMEK surgery requires.

For most other patients, however, DMEK is the

superior choice. It offers better and faster visual results, is associated with fewer severe complications, and requires no extra energy or expense (Table 1). It is also a rewarding technique to learn, with many steps that will be familiar to surgeons with endothelial keratoplasty experience. Even beginners can achieve excellent visual outcomes.

Surgeons who mostly perform DSAEK may maintain that, in most cases, the procedure is good enough; however, if it were your eye, which surgery would you choose? ■

*Gerrit R.J. Melles, MD, PhD, practices at the Netherlands Institute for Innovative Ocular Surgery, Rotterdam, the Melles Cornea Clinic Rotterdam, and Amnitrans EyeBank Rotterdam, Netherlands. Dr. Melles states that he is a consultant to DORC International. He may be reached at tel: +31 10 297 4444; e-mail: melles@nijos.com.*

*Jack S. Parker, MD, is a corneal fellow at the Netherlands Institute for Innovative Ocular Surgery in Rotterdam, the Melles Cornea Clinic Rotterdam, Netherlands, and a resident physician at the UAB Callahan Eye Hospital in Birmingham, Alabama. Dr. Parker states that he has no financial interest in the products or companies mentioned. He may be reached at tel: +1 205 543 0393; e-mail: parker@nijos.com.*

1. Melles GR, Lander F, Rietveld FJ. Transplantation of Descemet's membrane carrying viable endothelium through a small scleral incision. *Cornea*. 2002;21:415-418.
2. Anshu A, Price MO, Tan DT, et al. Endothelial keratoplasty: a revolution in evolution. *Surv Ophthalmol*. 2012;57:236-252.
3. van Dijk K, Ham L, Tse WH, et al. Near complete visual recovery and refractive stability in modern corneal transplantation: Descemet membrane endothelial keratoplasty (DMEK). *Cont Lens Anterior Eye*. 2013;36:13-21.
4. Guerra FP, Anshu A, Price MO, et al. Endothelial keratoplasty: fellow eyes comparison of Descemet stripping automated endothelial keratoplasty and Descemet membrane endothelial keratoplasty. *Cornea*. 2011;30:1382-1386.
5. Ham L, Dapena I, van der Wees J, et al. Secondary DMEK for poor visual outcome after DSEK: Donor posterior stroma may limit visual acuity in endothelial keratoplasty. *Cornea*. 2010;29:1278-1283.
6. Dapena I, Ham L, Droutsas K, et al. Learning curve in Descemet's membrane endothelial keratoplasty: First series of 135 consecutive cases. *Ophthalmology*. 2011;118:2147-2154.
7. Anshu A, Price MO, Price FW Jr. Risk of corneal transplant rejection significantly reduced with Descemet's membrane endothelial keratoplasty. *Ophthalmology*. 2012;119:536-540.
8. Naveiras M, Dirisamer, Parker J, et al. Causes of glaucoma after Descemet membrane endothelial keratoplasty (DMEK). *Am J Ophthalmol*. 2012;153:958-966.
9. Parker J, Dirisamer M, Naveiras M, et al. Outcomes of Descemet membrane endothelial keratoplasty in phakic eyes. *J Cataract Refract Surg*. 2012;38:871-877.
10. Yeh RY, Quilendrin R, Musa FU, et al. Predictive value of optical coherence tomography in graft attachment after Descemet's membrane endothelial keratoplasty. *Ophthalmology*. 2013;120:240-245.
11. Tourtas T, Laaser K, Bachmann BO, et al. Descemet membrane endothelial keratoplasty versus Descemet stripping automated endothelial keratoplasty. *Am J Ophthalmol*. 2012;153:1082-1090.
12. Li JY, Terry MA, Goshe J, et al. Three-year visual acuity outcomes after Descemet's stripping automated endothelial keratoplasty. *Ophthalmology*. 2012;119:1126-1129.
13. Li JY, Terry MA, Goshe J, et al. Graft rejection after Descemet's stripping automated endothelial keratoplasty. *Ophthalmology*. 2012;119:90-94.
14. Price MO, Gorovoy M, Price FW Jr, et al. Descemet's stripping automated endothelial keratoplasty. Three-year graft and endothelial cell survival compared with penetrating keratoplasty. *Ophthalmology*. 2013;120:246-251.
15. Groeneveld-van Beek EA, Lie J, van der Wees J, et al. Standardized 'no-touch' donor tissue preparation for DALK and DMEK: Harvesting undamaged anterior and posterior transplants from the same donor cornea. *Acta Ophthalmol*. 2013;91:145-150.